

Cranio-Maxillofacial and Dental Findings in Albright's Hereditary Osteodystrophy and Pseudohypoparathyroidism

Matthias Schlund, MD¹ , Arnaud Depeyre, MD, MSc²,
Florence Kohler, MD³, Romain Nicot, MD, MSc¹,
and Joël Ferri, MD, PhD¹

The Cleft Palate-Craniofacial Journal
1-6

© 2018, American Cleft Palate-Craniofacial Association
Article reuse guidelines:
sagepub.com/journals-permissions
DOI: 10.1177/1055665618814661
journals.sagepub.com/home/cpc



Abstract

Introduction: The clinical phenotype of pseudohypoparathyroidism (PHP) is caused by Albright's Hereditary Osteodystrophy (AHO). Often, "round face" the only facial clinical sign reported in the literature. The aim of this study was to highlight various cranio-maxillofacial clinical findings associated with AHO.

Results: Four patients presented with PHP type 1a. Only one patient exhibited the classical round face. All patients exhibited dental anomalies, class III malocclusion with maxillary retrusion, and a copper beaten appearance of the skull. One suffered from craniosynostosis.

Conclusion: The frequency of craniofacial and dental features associated with malocclusion should prompt careful follow-up, particularly during facial growth, in patients with AHO.

Keywords

craniofacial growth, dental anomalies, dental arch, dental occlusion, craniofacial morphology, facial growth, facial morphology, maxilla, midfacial growth, tooth agenesis, tooth development

Introduction

Pseudohypoparathyroidism (PHP) is a rare disease, with a prevalence of 1/100000 (Linglart et al., 2017), that was first described by Fuller Albright in 1942 (Albright et al., 1942). Pseudohypoparathyroidism is a heterogeneous group of disease characterized by parathyroid hormone (PTH) end-organ resistance. There are 2 types of PHP-based impairment in the PTH signal transduction pathway: type 1 exhibits impaired cyclic adenosine monophosphate (cAMP) response, whereas cAMP response to PTH is conserved in type 2 (Clarke et al., 2016). The etiology of PHP type 1 is dysfunction of the α -subunit of the heterotrimeric protein Gs due to GNAS gene (locus 20q13.3) congenital lesion: loss-of-function mutation in type 1a (exon 1-13) and 1c (exon 13) or methylation abnormalities in type 1b (Levine, 2012; Tafaj and Jüppner, 2017). The clinical phenotype of PHP is caused by Albright's Hereditary Osteodystrophy (AHO), which is only associated with PHP type 1a and 1c (Mantovani, 2011); although certain cases of type 1b PHP have exhibited mild AHO (Clarke et al., 2016; Tafaj and Jüppner, 2017; Sano et al., 2018). In addition, AHO is associated with pseudo-pseudohypoparathyroidism (PPHP),

a kind of PHP type 1a without hormonal resistance, also described by Fuller Albright (Albright et al., 1952). The dichotomy between PPHP and PHP type 1a follows the pattern of mutation inheritance: maternal inheritance of the mutation leads to PHP type 1a, whereas paternal inheritance of the mutation leads to PPHP (Wilson et al., 1994).

Typically, AHO is associated with the following clinical findings: ectopic calcification (often subcutaneous), short stature, stocky build, central obesity, brachydactyly, mental retardation, and a round face (Eyre and Reed, 1971; Fitch, 1982;

¹ Oral and Maxillofacial Surgery Department, Roger Salengro Hospital, CHU Lille, University of Lille, Lille, France

² Oral and Maxillofacial Surgery Department, Estaing Hospital, CHU Clermont Ferrand, University of Auvergne, Clermont Ferrand, France

³ Endocrinology and Metabolic diseases, Claude Huriez Hospital, CHU Lille, University of Lille, Lille, France

Corresponding Author:

Matthias Schlund, MD, Service de Chirurgie Maxillo-Faciale et Stomatologie, Hôpital Roger Salengro, Rue Emile Laine, 59037-Lille-Cedex, France.
Email: matthias.schlund@chru-lille.fr

Prendiville et al., 1992; Mantovani, 2011; Clarke et al., 2016; Mantovani et al., 2018). Round face is the only facial clinical sign that has been classically described. The aim of this study is to highlight various craniomaxillofacial clinical findings based on cases referred to our institution.

Material and Methods

We retrospectively included 4 patients who presented with AHO at the Oral and Maxillofacial Surgery Department of the University Hospital of Lille, France. Their medical files were reviewed to highlight clinical manifestations in the maxillofacial area. We followed the guidelines of Declaration of Helsinki for this investigation.

Results

Each patient (2 men and 2 women) presented with PHP type 1a and related AHO that was genetically confirmed. The 2 male patients were brothers. The first male patient suffered from craniosynostosis, which was treated at another department with a craniocervical decompression, followed by parietal osteotomies and finally fronto-orbital distraction. He was 15 years old at his first visit. He exhibited strabismus, a low nasal bridge, and a short neck (Figure 1A, B). He presented with class III malocclusion due to severe maxillary retrusion, several impacted teeth (all maxillary molars, right maxillary central incisor, and left second mandibular premolar), and dental dysplasia with shortened roots and open apices (Figure 1C, E). His skull radiograph showed a copper beaten appearance and hyperostosis of the calvaria (Figure 1D). However, he did not have a notably round face. He also suffered from severe sleep apnea.

The second male patient, or the younger brother, was 14 years old when he first presented. He did not have a notably round face as well, and his nose and neck were normal (Figure 2A, B). He exhibited class III malocclusion due to a maxillary retrusion, mandibular asymmetry with left deviation, impacted right maxillary second molar, delayed eruption of both maxillary second premolars, and dental dysplasia with shortened roots and open apices (Figure 2C, E). His skull radiograph showed a copper beaten appearance and hyperostosis of the calvaria (Figure 2D).

The third patient was a 13-year-old girl who exhibited a round face with a low nasal bridge, and a short neck (Figure 3A, B). She presented with class III malocclusion due to maxillary retrusion, and teeth agenesis (right mandibular first premolar and left mandibular second premolar; Figure 3C, E). Her skull radiograph showed a copper beaten appearance (Figure 3D). She suffered from severe obstructive sleep apnea.

The fourth patient was a 54-year-old woman who exhibited a low nasal bridge with a short neck; her face was not particularly round (Figure 4A, B). She presented with class III malocclusion due to maxillary retrusion and several impacted teeth (maxillary and mandibular second and third molars). Several teeth were missing due to past extractions, and her oral health was poor with mobility of all mandibular teeth and decay of the right first maxillary premolar

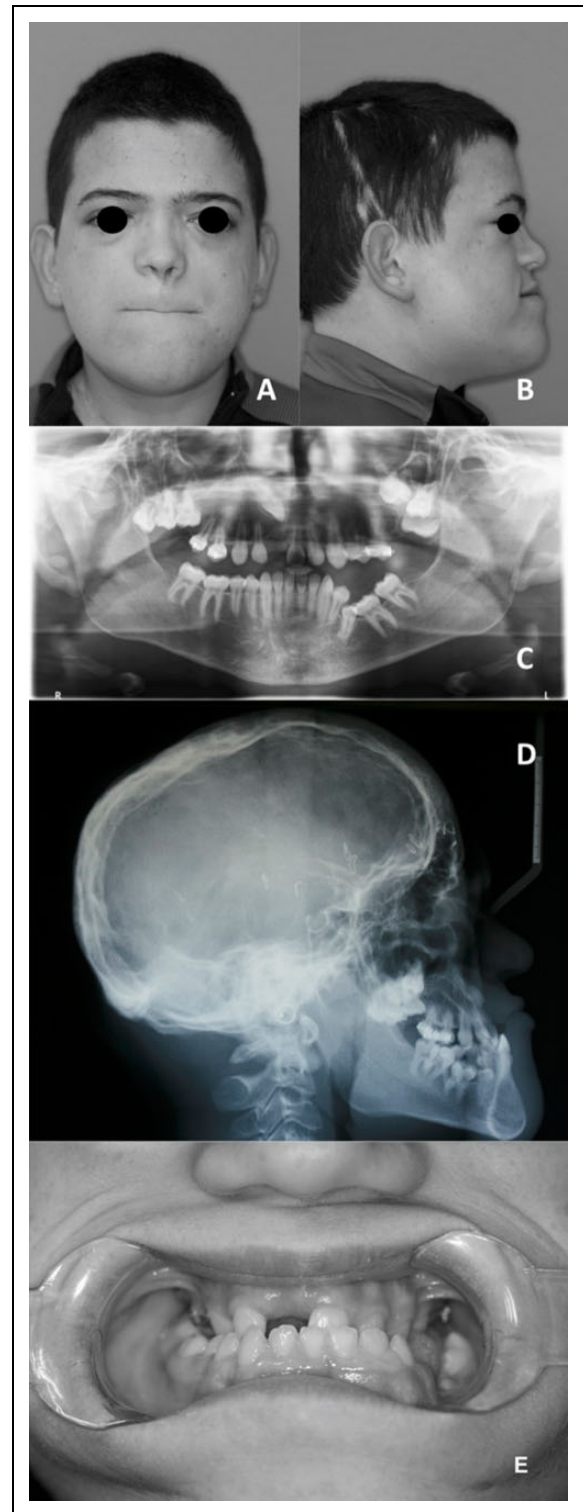


Figure 1. A, First patient, face photograph. There is no round face appearance. B, First patient, lateral view photograph showing a low nasal ridge, a short neck, and a maxillary retrusion. C, First patient, orthopantomogram showing several impacted teeth, dental dysplasia with shortened roots, and open apices. D, First patient, skull radiograph showing a copper beaten appearance and hyperostosis of the calvaria. E, First patient, occlusal photograph showing a class III malocclusion.

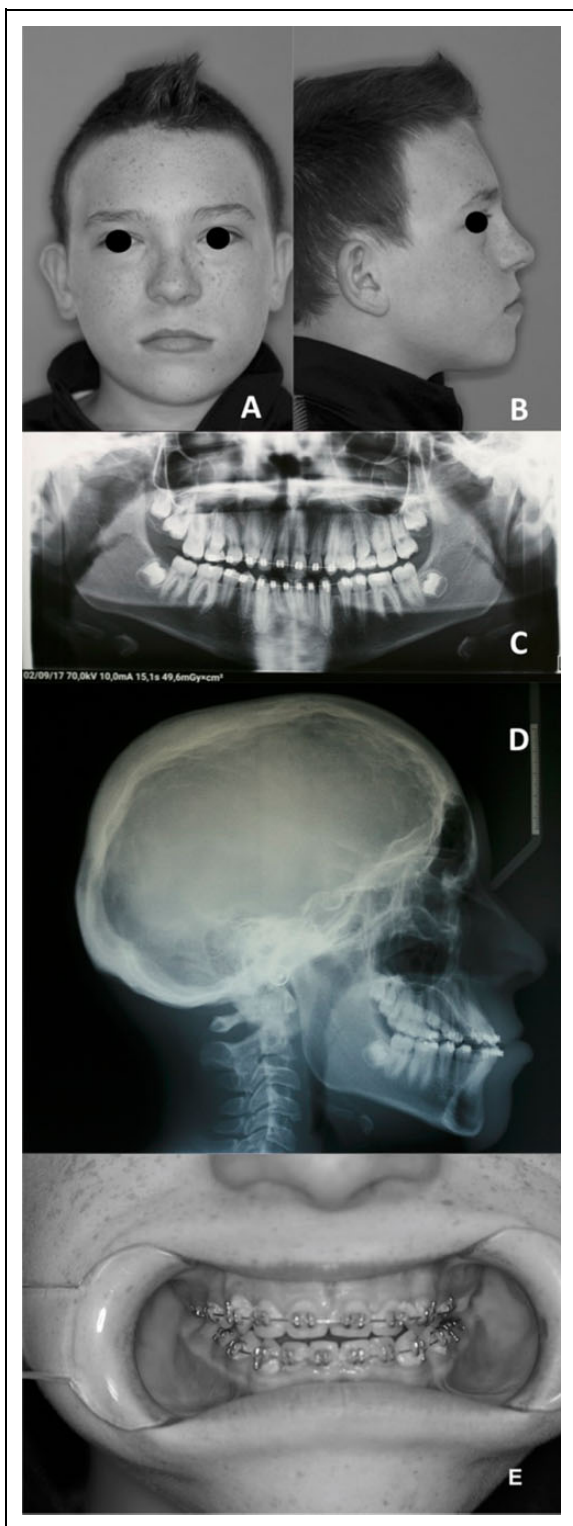


Figure 2. A, Second patient, face photograph showing a left mandibular deviation. There is no round face appearance. B, Second patient, lateral view photograph showing a normal nose and neck, there is a maxillary retrusion. C, Second patient, orthopantomogram showing impacted right maxillary second molar, delayed eruption of both maxillary second premolars, and dental dysplasia with shortened roots and open apices. D, Second patient, skull radiograph showing a copper beaten appearance and hyperostosis of the calvaria. E, Second patient, occlusal photograph showing a class III malocclusion.

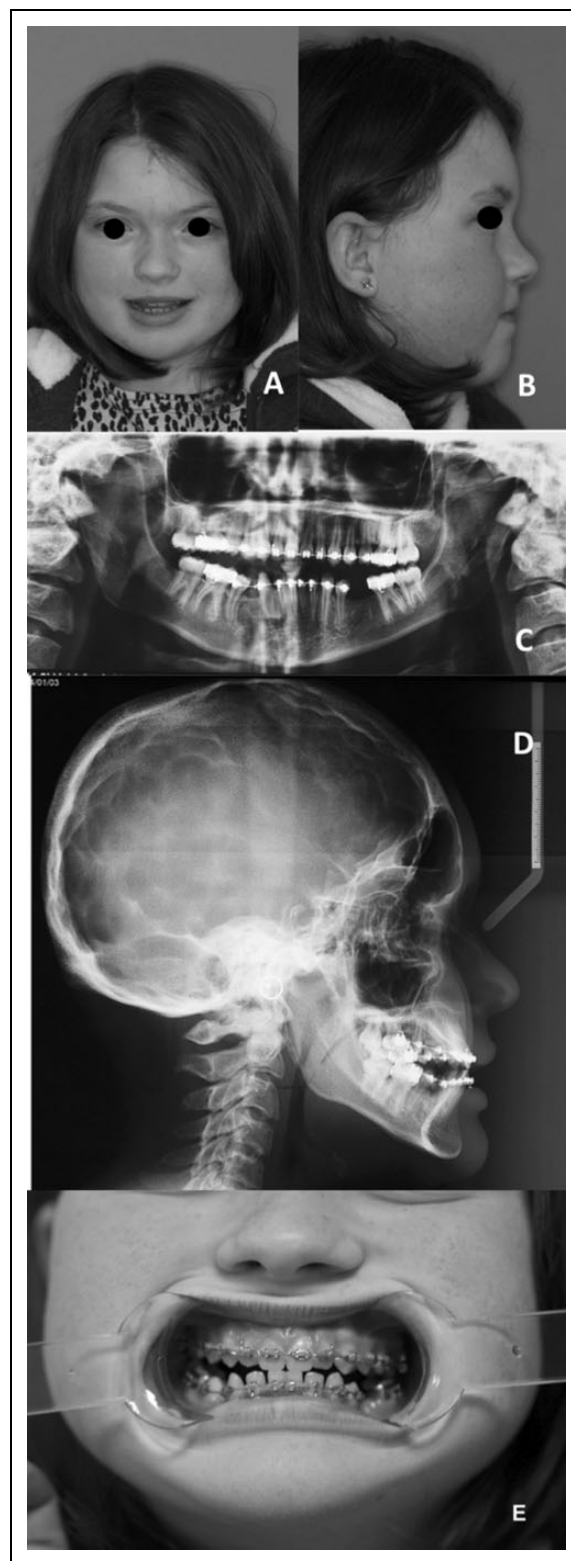


Figure 3. A, Third patient, face photograph showing a round face. B, Third patient, lateral view photograph showing a low nasal bridge and a short neck. C, Third patient, orthopantomogram showing teeth agenesis (right mandibular first premolar and left mandibular second premolar). D, Third patient, skull radiograph showing a copper beaten appearance. E, Third patient, occlusal photograph showing a class III malocclusion.

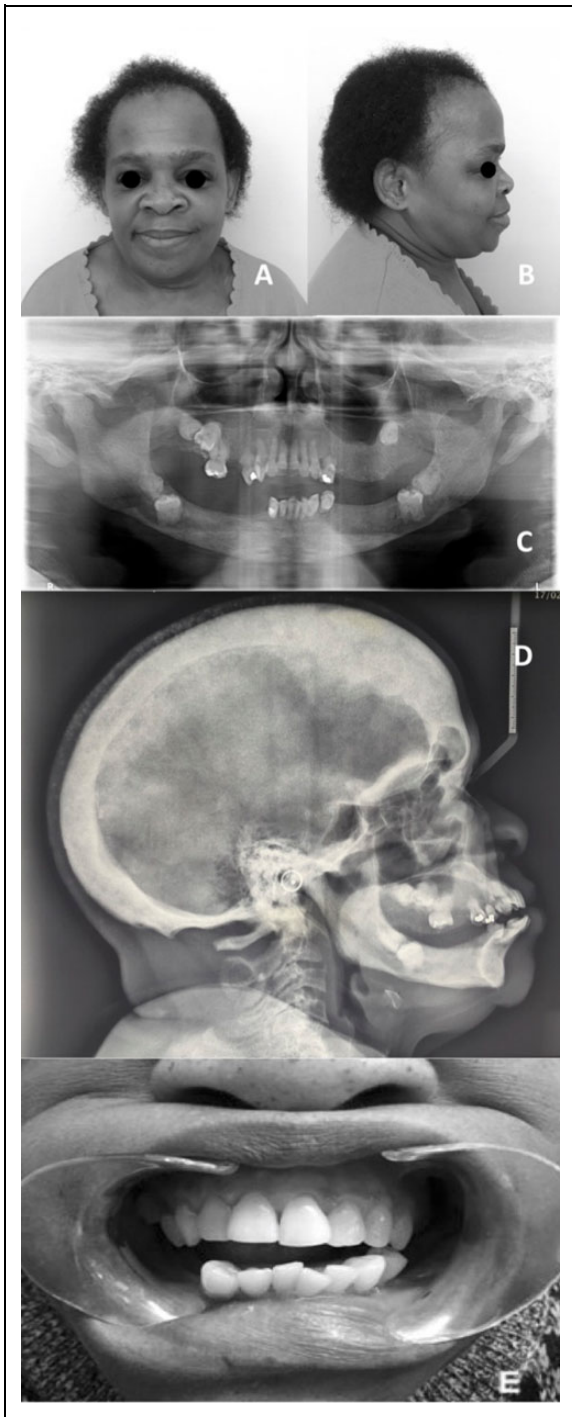


Figure 4. A, Fourth patient, face photograph. There is no round face appearance. B, Fourth patient, lateral view photograph showing a low nasal bridge with a short neck. C, Fourth patient, orthopantomogram showing several impacted teeth. D, Fourth patient, skull radiograph showing a copper beaten appearance and marked hyperostosis of the calvaria. E, Fourth patient, occlusal photograph showing a class III malocclusion and missing teeth.

(Figure 4C, E). Her skull radiograph showed a copper beaten appearance and marked hyperostosis of the calvaria (Figure 4D).

Discussion

Albright's Hereditary Osteodystrophy and PHP are rare diseases that are well known to endocrinologists. Although clinical findings of the facial region are heterogeneous and never pathognomonic, we felt that "round face" as the only facial sign usually mentioned in available original articles (Mantovani et al., 2010; Mantovani, 2011; Cho et al., 2013; Kottler, 2015; Thiele et al., 2015; Clarke et al., 2016; Thiele et al., 2016; Turan, 2017; Tafaj and Jüppner, 2017; Sano et al., 2018; Chu et al., 2018) was very unspecific. Moreover, since obesity is a part of the AHO phenotype, round face could be the consequence of this extra weight as well. The two other morphologic clinical findings of the face classically associated with AHO are a low nasal bridge and a short neck (Fitch, 1982; Gorlin et al., 2001). These signs have not been mentioned in available original articles (Mantovani et al., 2010; Mantovani, 2011; Cho et al., 2013; Kottler, 2015; Thiele et al., 2015; Clarke et al., 2016; Thiele et al., 2016; Turan, 2017; Tafaj and Jüppner, 2017; Chu et al., 2018; Sano et al., 2018) and have seldom been mentioned in case reports (Gomes et al., 2002; Stieler et al., 2011). In the present study, only 1 of the 4 patients exhibited a round face, whereas 3 patients presented with a low nasal bridge and a short neck.

Similarly, skull anomalies in AHO are not mentioned (Mantovani et al., 2010; Mantovani, 2011; Cho et al., 2013; Kottler, 2015; Thiele et al., 2015, 2016; Clarke et al., 2016; Tafaj and Jüppner, 2017; Turan, 2017; Sano et al., 2018; Chu et al., 2018), although they range from hyperostosis of the calvaria to craniosynostosis of multiple sutures (Fitch, 1982; Gorlin et al., 2001). In this study, all patients exhibited a copper beaten skull appearance, with one showing severe craniosynostosis and 2 showing calvarial hyperostosis. Therefore, anomalies of calvarial sutures seem to be frequent in AHO even if these do not often manifest clinically. This is consistent with the effect of hypoparathyroidism on bones: reduction of bone remodeling and turnover along with increased bone mass (Clarke, 2014). Patients with hypoparathyroidism usually exhibit increased cortical thickness on peripheral quantitative computed tomography analysis of radial bone (Chen et al., 2003) and on histomorphometric analysis of iliac bone (Rubin et al., 2008); this could explain the calvarial hyperostosis. On the other hand, bone forming surface, bone formation, and remodeling activation frequency are reduced owing to a decrease in mineralized surface and mineral apposition rate on cancellous, endocortical, and intracortical bones (Langdahl et al., 1996; Rubin et al., 2008), which could explain the malfunction of calvarial sutures.

Dental manifestations of AHO are seldom sought after: only 2 recent original article reported these (Clarke et al., 2016; Mantovani et al., 2018), and otherwise, such manifestations have only been described in case reports (Gomes et al., 2002; DuVal et al., 2007; Jeong et al., 2009; Hugar et al., 2014; Kuzel et al., 2017). Although these seem benign compared to hormonal resistance, these occur frequently, and all cases reported in this publication exhibited dental manifestations of AHO as well. The fact that we are part of an Oral and Maxillofacial Surgery Department could represent a bias, but it has been

reported that 33% of patients with AHO suffered from dental anomalies (Gorlin et al., 2001). Dental manifestations of AHO encompass impacted teeth, delayed eruption, dental agenesis, shortened roots with opened apices, widened root canals, and enamel hypoplasia (Ritchie, 1965; Gorlin et al., 2001). Our cases exhibited several impacted teeth, delayed eruption, dental agenesis, and shortened roots with open apices; this is consistent with findings from studies on PTH and dental development. Type I PTH/PTH-related protein receptor (PTHrP) was found in dental mesenchymal tissues adjacent to teeth and in alveolar bone (Aggarwal and Zavras, 2012). Schipani et al. (1997) showed that lack of PTHrP receptors reduced the number of ameloblasts with a disrupted odontoblastic layer; tooth eruption was absent. Philbrick et al. (1998) showed that PTHrP knock-out mice underwent progressive impaction of their teeth.

Of note, no association has been identified between malocclusion and AHO in past reviews or publications that focused on dental anomalies (Ritchie, 1965; Fitch, 1982; Gorlin et al., 2001). It has been described in case reports (Gomes et al., 2002; Jeong et al., 2009; Hugar et al., 2014), mostly as “malocclusion” without more precision. There was one case of open bite with dento-alveolar protrusion and bilateral condylar resorption (Gomes et al., 2002) and another case with class III malocclusion based on the published facial photographs (Jeong et al., 2009). In the present study, every patient showed class III malocclusion due to maxillary retrusion. The published case with condylar resorption (Gomes et al., 2002) also suffered from juvenile generalized rheumatoid arthritis, which could easily explain this resorption and subsequent malocclusion. Maxillary retrusion is a part of the diagnostic criteria established for inactivating PTH/PTHrP signaling disorder (iPPSD, see below). It could be linked to calvarial suture anomalies since cranial and facial growths are interconnected. Moreover, the cause of calvarial suture malfunction mentioned above would also lead to facial suture growth alterations. A deficiency in cranial growth due to the malfunction of cranial suture could explain the deficiency of maxillary growth. Thus, the frequency of dental anomalies and malocclusion should prompt careful dental follow-up, particularly during facial growth, in patients with AHO.

Finally, ophthalmologic anomalies were only discussed by Chu et al. (2018) in a recent publication. However, several ophthalmologic anomalies have been associated with AHO the most frequent being cataract; 56.2% in Chu et al. (2018) and 25% in Gorlin et al. (2001), along with strabismus, nystagmus, unequal size of pupils, blurring of disk margins, tortuosity of vessels, diplopia, microphthalmia, early optic atrophy, congenital macular degeneration, bilateral malformation of optic disks, and irregular pigmentation (Fitch, 1982; Gorlin et al., 2001). One patient in the present study suffered from strabismus.

The present classification of PHP (eg, type 1a, 1b, 1c, type 2, and PPHP) does not include molecular defect as a criterion and does not include other diseases with PTH signal transduction pathway impairment such as acrodysostosis type 1 and 2, Eiken and Blomstrand dysplasia, and autosomal dominant hypertension with brachydactyly. A new classification has been proposed by

the EuroPHP network (Thiele et al., 2016; Turan, 2017), wherein these diseases have been grouped under the new term “inactivating PTH/PTHrP signaling disorder” (iPPSD). Pseudohypoparathyroidism type 1a, type 1c, and PPHP would be known as iPPSD type 2. Major and minor criteria have been defined to diagnose iPPSD (Thiele et al., 2016): the disease is diagnosed when a combination of criteria is observed. One of the minor criteria is focused on the face (the sixth minor criterion), and the findings include flat nasal bridge and/or maxillary hypoplasia and/or round face. Round face is associated with AHO, whereas flat nasal bridge and maxillary hypoplasia are associated with acrodysostosis. Flat nasal bridge was considered as a classical sign of AHO (Fitch, 1982; Gorlin et al., 2001), and several cases of AHO with flat nasal bridge have been published recently (Gomes et al., 2002; Stieler et al., 2011). In the present study, 3 patients exhibited this sign. Although maxillary hypoplasia is not classically associated with AHO, every patient in this study exhibited maxillary retrusion and class III malocclusion.

Conclusion

We report 4 cases of AHO with PHP type 1a that exhibited dental anomalies, malocclusion, and skull anomalies. In terms of cranio-maxillofacial evaluation, AHO should not be restricted to the “round face” sign. Dental and craniofacial growth anomalies should be systematically investigated and treated.


Declaration of Conflicting Interests

The author(s) declared no potential conflicts of interest with respect to the research, authorship, and/or publication of this article.

Funding

The author(s) received no financial support for the research, authorship, and/or publication of this article.

ORCID iD

Matthias Schlund, MD  <https://orcid.org/0000-0002-5836-7169>

References

- Aggarwal P, Zavras A. Parathyroid hormone and its effects on dental tissues. *Oral Dis.* 2012;18(1):48-54.
- Albright F, Burnet CH, Smith CH, Parson W. Pseudohypoparathyroidism: an example of ‘Seabright-Bantam Syndrome.’ *Endocrinology.* 1942;30:922-32.
- Albright F, Forbes AP, Henneman PH. Pseudo-pseudohypoparathyroidism. *Trans Assoc Am Physicians.* 1952;65:337-3350.
- Chen Q, Kaji H, Iu MF, Nomura R, Sowa H, Yamauchi M, Tsukamoto T, Sugimoto T, Chihara K. Effects of an excess and a deficiency of endogenous parathyroid hormone on volumetric bone mineral density and bone geometry determined by peripheral quantitative computed tomography in female subjects. *J Clin Endocrinol Metab.* 2003;88(10):4655-4658.
- Cho SY, Yoon YA, Ki CS, Huh HJ, Yoo HW, Lee BH, Kim GH, Yoo JH, Kim SY, Kim SJ, et al. Clinical characterization and molecular classification of 12 Korean patients with pseudohypoparathyroidism

- and pseudopseudohypoparathyroidism. *Exp Clin Endocrinol Diabetes*. 2013;121(9):539-545.
- Chu X, Zhu Y, Wang O, Nie M, Quan T, Xue Y, Wang W, Jiang Y, Li M, Xia W, et al. Clinical and genetic characteristics of pseudohypoparathyroidism in the Chinese population. *Clin Endocrinol (Oxf)*. 2018;88(2):285-294.
- Clarke BL. Bone disease in hypoparathyroidism. *Arq Bras Endocrinol Metabol*. 2014;58(5):545-552.
- Clarke BL, Brown EM, Collins MT, Jüppner H, Lakatos P, Levine MA, Mannstadt MM, Bilezikian JP, Romanischen AF, Thakker RV. Epidemiology and diagnosis of hypoparathyroidism. *J Clin Endocrinol Metab*. 2016;101(6):2284-2299.
- DuVal MG, Davidson S, Ho A, Cohen R, Park M, Nourian S, Baker G, Sándor GKB. Albright's hereditary osteodystrophy with extensive heterotopic ossification of the oral and maxillofacial region: how fetuin research may help a seemingly impossible condition. *J Can Dent Assoc*. 2007;73(9):845-850.
- Eyre WG, Reed WB. Albright's hereditary osteodystrophy with cutaneous bone formation. *Arch Dermatol*. 1971;104(6):634-642.
- Fitch N. Albright's hereditary osteodystrophy: a review. *Am J Med Genet*. 1982;11(1):11-29.
- Gomes MF, Camargo AMA, Sampaio TA, Graziozi AMOC, Armond AM. Oral manifestations of Albright hereditary osteodystrophy: a case report. *Rev Hosp Clin Fac Med Sao Paulo*. 2002;57(4):161-166.
- Gorlin RJ, Cohen M Jr, Hennekam RCM. *Syndromes of the Head and Neck*. Oxford, England: Oxford University Press; 2001.
- Hugar D, Sajjanshetty S, Hugar S, Kadani M. Albright hereditary osteodystrophy: a case report. *Journal of Clinical and Diagnostic Research: JCDR*. 2014;8(10):ZD28-ZD30.
- Jeong KH, Lew BL, Sim WY. Osteoma cutis as the presenting feature of Albright hereditary osteodystrophy associated with pseudopseudohypoparathyroidism. *Ann Dermatol*. 2009;21(2):154-158.
- Kottler ML. Paternal GNAS mutations: which phenotypes? What genetic counseling? [in French]. *Annales D'endocrinologie*. 2015;76(2):105-109.
- Kuzel AR, Lodhi MU, Rahim M. Classic and non-classic features in pseudohypoparathyroidism: case study and brief literature review. *Cureus*. 2017;9(11):e1878.
- Langdahl BL, Mortensen L, Vesterby A, Eriksen EF, Charles P. Bone histomorphometry in hypoparathyroid patients treated with vitamin D. *Bone*. 1996;18(2):103-108.
- Levine MA. An update on the clinical and molecular characteristics of pseudohypoparathyroidism. *Curr Opin Endocrinol Diabetes Obes*. 2012;19(6):443-451.
- Linglart A, Mantovani G, Garin I, Usardi A, Elli FM, de Nanclares GP. The importance of networking in pseudohypoparathyroidism: EuroPHP Network and Patient Support Associations. *Pediatr Endocrinol Rev*. 2017;15(suppl 1):92-97.
- Mantovani G. Clinical review: pseudohypoparathyroidism: diagnosis and treatment. *J Clin Endocrinol Metab*. 2011;96(10):3020-3030.
- Mantovani G, Bastepe M, Monk D, de Sanctis L, Thiele S, Usardi A, Ahmed SF, Bufo R, Choplin T, De Filippo G, et al. Diagnosis and management of pseudohypoparathyroidism and related disorders: first international consensus statement. *Nat Rev Endocrinol*. 2018;14(8):476-500.
- Mantovani G, de Sanctis L, Barbieri AM, Elli FM, Bollati V, Vaira V, Labarile P, Bondioni S, Peverelli E, Lania AG, et al. Pseudohypoparathyroidism and GNAS epigenetic defects: clinical evaluation of Albright hereditary osteodystrophy and molecular analysis in 40 patients. *J Clin Endocrinol Metab*. 2010;95(2):651-658.
- Philbrick WM, Dreyer BE, Nakchbandi IA, Karaplis AC. Parathyroid hormone-related protein is required for tooth eruption. *Proc Natl Acad Sci U S A*. 1998;95(20):11846-11851.
- Prendiville JS, Lucky AW, Mallory SB, Mughal Z, Mimouni F, Langman CB. Osteoma cutis as a presenting sign of pseudohypoparathyroidism. *Pediatr Dermatol*. 1992;9(1):11-18.
- Ritchie GM. Dental manifestations of pseudohypoparathyroidism. *Arch Dis Child*. 1965;40(213):565-572.
- Rubin MR, Dempster DW, Zhou H, Shane E, Nickolas T, Sliney J, Silverberg SJ, Bilezikian JP. Dynamic and structural properties of the skeleton in hypoparathyroidism. *J Bone Miner Res*. 2008;23(12):2018-2024.
- Sano S, Nakamura A, Matsubara K, Nagasaki K, Fukami M, Kagami M, Ogata T. (Epi)genotype-phenotype analysis in 69 Japanese patients with pseudohypoparathyroidism type I. *J Endocr Soc*. 2018;2(1):9-23.
- Schipani E, Lanske B, Hunzelman J, Luz A, Kovacs CS, Lee K, Pirro A, Kronenberg HM, Jüppner H. Targeted expression of constitutively active receptors for parathyroid hormone and parathyroid hormone-related peptide delays endochondral bone formation and rescues mice that lack parathyroid hormone-related peptide. *Proc Natl Acad Sci U S A*. 1997;94(25):13689-13694.
- Stieler K, Schnabel D, Atugoda S, Sterry W, Blume-Peytavi U. Albright hereditary osteodystrophy. *Pediatr Dermatol*. 2011;28(2):135-137.
- Tafaj O, Jüppner H. Pseudohypoparathyroidism: one gene, several syndromes. *J Endocrinol Invest*. 2017;40(4):347-356.
- Thiele S, Mantovani G, Barlier A, Boldrin V, Bordogna P, De Sanctis L, Elli FM, Freson K, Garin I, Grybek V. From pseudohypoparathyroidism to Inactivating PTH/PTHrP Signalling Disorder (iPPSD), a novel classification proposed by the EuroPHP network. *Eur J Endocrinol*. 2016;175(6):P1-P17.
- Thiele S, Werner R, Grötzinger J, Brix B, Staedt P, Struve D, Reiz B, Farida J, Hiort O. A positive genotype-phenotype correlation in a large cohort of patients with pseudohypoparathyroidism type Ia and pseudo-pseudohypoparathyroidism and 33 newly identified mutations in the GNAS gene. *Mol Genet Genomic Med*. 2015;3(2):111-120.
- Turan S. Current nomenclature of pseudohypoparathyroidism: inactivating parathyroid hormone/parathyroid hormone-related protein signaling disorder. *J Clin Res Pediatr Endocrinol*. 2017;9(suppl 2):58-68.
- Wilson LC, Oude Luttikhuis ME, Clayton PT, Fraser WD, Trembath RC. Parental origin of Gs alpha gene mutations in Albright's hereditary osteodystrophy. *J Med Genet*. 1994;31(11):835-839.